

Overheated and melted intracranial pressure transducer as cause of thermal brain injury during magnetic resonance imaging

Case report

REIICHIRO TANAKA, M.D.,¹ TETSUYA YUMOTO, M.D.,² NAOKI SHIBA, M.D.,¹ MOTOHISA OKAWA, M.D., PH.D.,³ TAKAO YASUHARA, M.D., PH.D.,⁴ TOMOTSUGU ICHIKAWA, M.D., PH.D.,⁵ KOJI TOKUNAGA, M.D., PH.D.,⁵ ISAO DATE, M.D., PH.D.,⁵ AND YOSHIHITO UJIKE, M.D., PH.D.¹

¹Department of Critical Care and Emergency Medicine, Okayama University Hospital; ²Department of Health Science, College of Life Science, Kurashiki University of Science and The Arts; ³Department of Neurological Surgery, Okayama University Graduate School of Medicine, Okayama; ⁴Department of Surgery, National Hospital Organization Mito Medical Center, Ibaraki; and ⁵Spinal Cord Treatment Center, Shin Komonji Hospital, Fukuoka, Japan

Magnetic resonance imaging is used with increasing frequency to provide accurate clinical information in cases of acute brain injury, and it is important to ensure that intracranial pressure (ICP) monitoring devices are both safe and accurate inside the MRI suite. A rare case of thermal brain injury during MRI associated with an overheated ICP transducer is reported.

This 20-year-old man had sustained a severe contusion of the right temporal and parietal lobes during a motor vehicle accident. An MR-compatible ICP transducer was placed in the left frontal lobe. The patient was treated with therapeutic hypothermia, barbiturate therapy, partial right temporal lobectomy, and decompressive craniectomy. Immediately after MRI examination on hospital Day 6, the ICP monitor was found to have stopped working, and the transducer was subsequently removed. The patient developed meningitis after this event, and repeat MRI revealed additional brain injury deep in the white matter on the left side, at the location of the ICP transducer. It is suspected that this new injury was caused by heating due to the radiofrequency radiation used in MRI because it was ascertained that the tip of the transducer had been melted and scorched. Scanning conditions—including configuration of the transducer, MRI parameters such as the type of radiofrequency coil, and the specific absorption rate limit—deviated from the manufacturer’s recommendations. In cooperation with the manufacturer, the authors developed a precautionary tag describing guidelines for safe MR scanning to attach to the display unit of the product.

Strict adherence to the manufacturer’s guidelines is very important for preventing serious complications in patients with ICP monitors undergoing MRI examinations.
(<http://thejns.org/doi/abs/10.3171/2012.9.JNS12738>)

KEY WORDS • antenna effect • electromagnetic induction heating • intracranial pressure monitor • magnetic resonance imaging • meningitis • thermal brain injury

CONTINUOUS ICP monitoring is essential in the standard management of patients with a wide range of intracranial conditions, including severe head injury. As MRI often provides important clinical information in the acute stage of brain injury, ICP monitoring in patients undergoing MRI examination is growing

increasingly common. However, given that there have been a substantial number of thermal injuries caused by the effect of the RF radiation used in MRI on monitoring devices, special care must be taken to ensure the safety and accuracy of ICP monitoring devices in the MRI setting.^{3,8–11,20,22,25–27}

Two types of systems are used to monitor ICP: fluid-coupled systems, which use an intraventricular catheter, and non-fluid-coupled systems, which use one of the variety of intracranial miniature transducers that have been developed over the past 25 years. Although use of

Abbreviations used in this paper: DBS = deep brain stimulation; FDA = US Food and Drug Administration; GCS = Glasgow Coma Scale; ICP = intracranial pressure; RF = radiofrequency; SAR = specific absorption rate; WBC = white blood cell.

Thermal brain injury and ICP transducer

an intraventricular catheter was once the gold standard, commercially available intracranial transducers offer advantages in terms of ease of insertion and reduced risk of infection and are now used more commonly.^{7,14,16,19,28,30}

The FDA has provided useful definitions regarding the safety of clinical equipment in the MR environment. A device is defined as “MR safe” when its use in MRI has been demonstrated to present no additional risk to the patient but the MR environment may affect the quality of the diagnostic information. A device is defined as “MR compatible” when it is MR safe and has also been demonstrated to neither significantly affect the quality of the diagnostic information nor have its operations affected by the MR environment. The Codman MicroSensor (Johnson & Johnson, Codman & Shurtleff, Inc.) is considered an MR-compatible device in many countries of the European Union and also in Japan (although not in the US). It is not well known, however, that the manufacturer’s guidelines must be strictly followed, including configuration of the transducer in a specific geometry and adherence to the recommended parameters, such as using a 1.5-T MR system with a transmit/receive RF body coil, transmit body coil/receive-only head coil, or transmit/receive head coil; and limiting the SAR to 1.0 W/kg. The aim of this article is to present an unusual case of severe brain injury sustained in a traffic accident followed by a thermal brain injury, which we believe was caused by an overheated and melted Codman MicroSensor ICP transducer during MRI scanning, as a result of not strictly following the manufacturer’s guidelines.

Case Report

History and Presentation. This 20-year-old man was involved in a motor vehicle accident in October 2008 and was found unresponsive at the scene. He was transported by ambulance directly to the emergency room of the Critical Care and Emergency Medicine Department at Okayama University Hospital. On arrival, he had a blood pressure of 150/100 mm Hg, heart rate of 112 beats per minute, and GCS score of 7. Both pupils were 7.0 mm, round, and unreactive to light. Tracheal intubation was performed immediately after arrival in the emergency room. Radiography of the patient’s chest revealed bilateral pulmonary contusions and a fractured right clavicle. A subsequent CT scan of the chest revealed bilateral pulmonary contusions and fractured right transverse processes and vertebral arches of T5–7. A CT scan of the head demonstrated a right parietal fracture, no skull base fracture, contusion of the right temporoparietal lobe, right subdural hematoma, subarachnoid hemorrhage, and a slight shift of the midline to the left.

Initial Treatment, Lobectomy, and Decompressive Craniectomy. We inserted an ICP transducer (Codman MicroSensor; Johnson & Johnson, Codman & Shurtleff, Inc.) and obtained an initial ICP reading of 63 mm Hg and a cerebral perfusion pressure reading of 40 mm Hg. Therapeutic hypothermia at 32°C was started immediately after admission. However, in spite of intensive inter-

vention, including barbiturate therapy, the patient’s ICP remained higher than 40 mm Hg and a second head CT scan revealed a deterioration of brain swelling. A partial right temporal lobectomy and decompressive craniectomy were performed 8 hours after admission. The patient’s ICP decreased to 10–20 mm Hg postoperatively and a third head CT scan performed immediately after surgery showed decreased brain swelling.

Postoperative Course and Imaging Findings. A CT scan of the patient’s head on hospital Day 5 demonstrated improvement of brain swelling and showed that the tip of the ICP transducer was located in the parenchyma of the left frontal lobe near the frontal angle of the left lateral ventricle (Fig. 1A and B).

When therapeutic hypothermia was discontinued on Day 6, MRI was performed to evaluate the presence of intracranial lesions, including diffuse axonal injury, and any cervical spinal cord injury. The scans revealed contusions of the right temporoparietal lobe only, and no diffuse axonal injury or cervical spinal cord injury (Fig. 1C–E). No contusions were demonstrated in the left cerebral hemisphere.

After the scan, the patient was returned to the intensive care unit, where it became evident that the ICP monitoring system was no longer functioning. The transducer was removed and submitted to Johnson & Johnson without careful inspection.

Three days afterward (that is, on hospital Day 9), the patient developed neck stiffness and fever up to 40°C. Blood tests revealed a WBC count of 12,000/mm³, an increased proportion of immature leukocytes (band neutrophils), and a C-reactive protein level of 12.21 mg/dl.

On Day 10, blood tests revealed a WBC count of 20,950 cells/mm³ and a blood sugar level of 145 mg/dl. Cerebrospinal fluid examination revealed a WBC count of 5730 cells/mm³ with 80% polymorphonuclear neutrophils and 20% lymphocytes, an elevated protein content (312 mg/dl), and a decreased glucose concentration (33 mg/dl). Another head CT scan was performed (on Day 10), and the radiology report indicated that the low-density area in the left frontal lobe at the previous location of the ICP transducer, near the frontal angle of the left lateral ventricle, was slightly more conspicuous than in the head CT scan from Day 5 (Fig. 2A).

The patient’s condition was diagnosed as bacterial meningitis, and the relevance of the ICP transducer malfunction was not recognized at that time. Although the examination of a Gram-stained CSF smear showed no bacteria, antibiotic treatment was started immediately after the diagnosis of meningitis, on Day 10. Repeated culture of the CSF did not reveal any bacteria. The patient was treated with intravenously administered meropenem trihydrate 2 g/day for 9 days and intraspinal injection of gentamicin sulfate 10 mg/day for 5 days. The patient became afebrile and CSF findings showed a marked improvement on Day 17. His level of consciousness improved markedly (GCS score E4VTM6), although it became evident on Day 26 that he had total left hemiplegia.

A follow-up CT scan of the head was performed on Day 26 because blood testing revealed a WBC count of

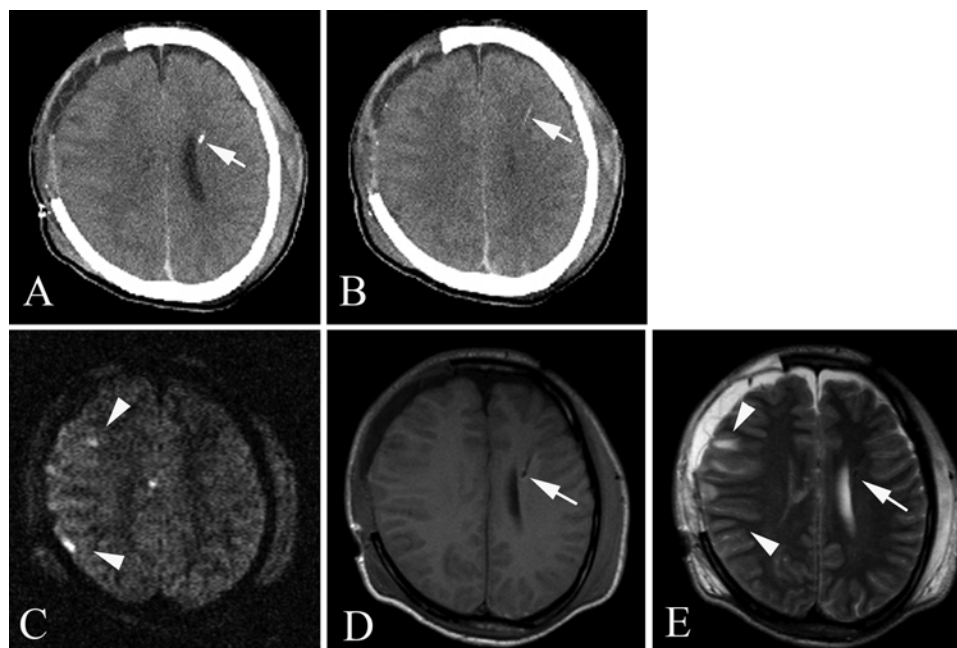


FIG. 1. **A and B:** Axial CT images obtained on Day 5 after right temporal lobectomy and decompressive craniectomy demonstrating improvement of brain swelling. The ICP transducer tip (*white arrows*) is located in the left frontal lobe parenchyma near the frontal angle of the left lateral ventricle. **C–E:** Axial MR images obtained on Day 6, including diffusion-weighted (C), T1-weighted (D), and T2-weighted (E) sequences. The diffusion-weighted and T2-weighted images demonstrate contusions of the right temporoparietal lobe (*white arrowheads*) but no diffuse axonal injury. No contusions are demonstrated in the left cerebral hemisphere. The T1-weighted and T2-weighted images also demonstrate that the ICP transducer tip (*white arrows*) is located in the left frontal lobe parenchyma near the frontal angle of the left lateral ventricle.

13,660 cells/mm and left shift, although the patient was afebrile. The CT scan revealed that the low-density area in the left frontal lobe near the frontal angle of the left lateral ventricle, where the ICP transducer had been located, remained almost unchanged.

This finding led to the suspicion of thermal brain injury caused by the overheated and melted ICP transducer during the MRI procedure. Contrast-enhanced CT scans on Day 27 and Gd-enhanced T1-weighted MRI scans on Day 28 revealed a ring-enhancing lesion (Fig. 2B and D). Diffusion-weighted and T2-weighted MRI on Day 28 revealed a well-circumscribed, ovoid, high-intensity lesion with a low-intensity center, approximately 26.5 mm in a diameter, in the left frontal lobe near the frontal angle of the left lateral ventricle, in the previous location of the ICP transducer (Fig. 2C and E). Furthermore, T2-weighted imaging revealed a high-intensity tract in a low-intensity center with a high-intensity small surrounding area, which did not have findings compatible with a brain abscess, such as a large high-intensity circumference indicating edema of the surrounding parenchyma (Fig. 2E). We diagnosed the lesion as a healing thermal brain injury, because the combination of a small high-intensity area surrounding the lesion and a low-intensity central area on T2-weighted MR images, which corresponded to the ring-enhancing lesion evident on Gd-enhanced T1-weighted scans, was compatible with coagulative necrosis.

It was decided to continue conservative treatment without antibiotic therapy, because both physical examination findings and blood testing indicated that the in-

flammation had decreased, and the CT scan obtained on Day 27 demonstrated a reduction in the low-density area compared with Day 10 (Fig. 2A and B). An MRI study of the head on Day 41 revealed a further reduction in the size of the lesion. Cranial osteoplasty was performed on Day 47 and there were no postoperative complications. The patient made an excellent cognitive recovery and was discharged to a rehabilitation unit on Day 59.

Investigation of the Cause of the Incident. When we removed the ICP transducer from the patient on Day 6, we submitted it to Johnson & Johnson and asked them to investigate why it had stopped working. The Medical Accident Investigation Board at Okayama University Hospital discussed the cause of the incident several times and asked Johnson & Johnson to undertake an in-depth analysis. Four months after the incident, they reported that the transducer was melted and scorched 4–13 mm from the tip, with the most melted portion being 7–12 mm from the tip (Fig. 3 left). Radiophotography showed that the 3 copper conducting wires in the nylon-coated transducer had snapped at 9 mm from the tip (Fig. 3 right). They also reported the possibility that local bending of the ICP transducer, which was observed at 11 mm from the tip, had resulted in twin deformation of the conductor with consequent high localized electrical impedance. However, as the medical doctor who had inserted the Codman MicroSensor transducer testified that he had done so without bending it, this apparent bend in the transducer may have resulted from the melting. Johnson & Johnson also indicated that the conductor of the ICP transducer

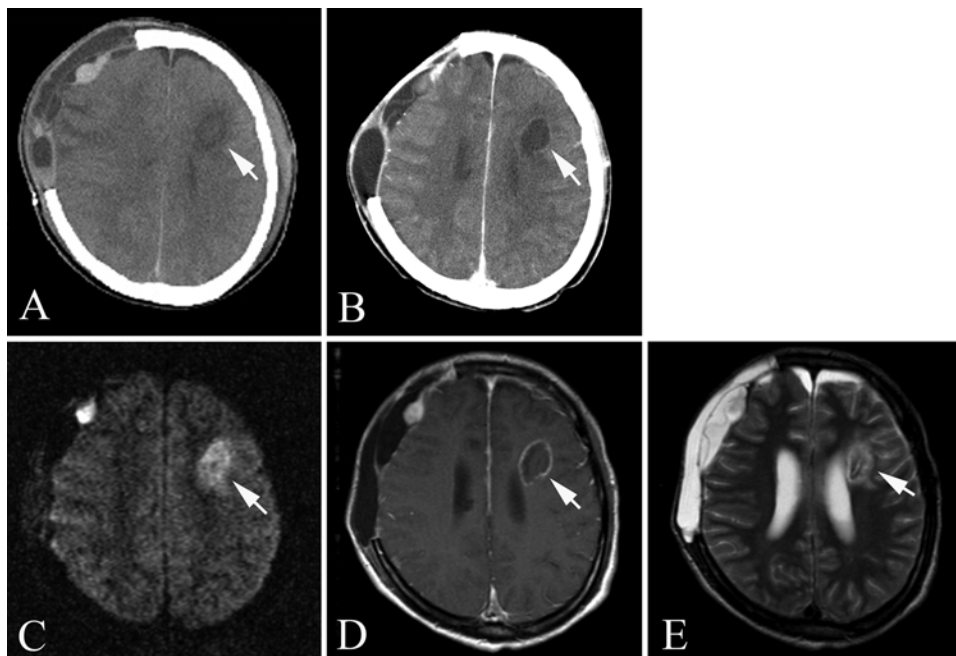


FIG. 2. **A:** Axial CT image obtained on Day 10 demonstrating that the low-density area in the left frontal lobe parenchyma (*white arrow*), in the previous location of the ICP transducer, is slightly more conspicuous than on Day 5. **B:** Contrast-enhanced CT image obtained on Day 27 demonstrating a reduction in the low-density area (*white arrow*) compared with Day 10. **C–E:** Axial MR images obtained on Day 28, including diffusion-weighted (C), Gd-enhanced T1-weighted (D), and T2-weighted (E) sequences. The diffusion-weighted and T2-weighted images demonstrate a high-intensity lesion with a low-intensity center approximately 26.5 mm in diameter (*white arrow*), which is a well-circumscribed ovoid mass deep in the white matter of the left frontal lobe near the frontal angle of the left lateral ventricle, in the previous location of the ICP transducer. The T2-weighted image also demonstrates a high-intensity tract inside a low-intensity center surrounded by a small high-intensity area. The high-intensity tract corresponds to the shape and location of the tip of the ICP transducer. The Gd-enhanced T1-weighted MR image reveals a ring-enhancing lesion (*white arrow*). The ring enhancement in the Gd-enhanced T1-weighted image (D) corresponds to the small area of high signal intensity surrounding the lesion in the T2-weighted image (E).

might form a closed loop if configured in parallel with the RF coil, or if it was touching the patient on another part of his body other than where it was inserted. They concluded that under these conditions, the RF energy of the MR scanner might induce an electrical current of sufficient magnitude to increase the temperature of the tip of the transducer, melt the nylon coating, and snap the




FIG. 3. Photographs of the Codman MicroSensor ICP transducer. **Left:** Enlargement of the photograph of the strain gauge transducer of the Codman MicroSensor used in the current case. (Each scale interval represents 1 mm.) Although the copper wire is not exposed, the transducer is melted and scorched at 7–12 mm from the tip. A black substance can be seen on the surface of the transducer tip. The appearance of this coating was consistent with charred blood. **Right:** Enlargement of a portion of a radiograph of the Codman MicroSensor ICP transducer removed from our patient demonstrating that the 3 copper conducting wires within the nylon coating were completely broken at 9 mm from the tip. Original magnification $\times 150$.

conducting wires. Furthermore, the Medical Device Reporting document prepared by the Quality Assurance Department of Johnson & Johnson K.K. Vigilance and Safety Group provided information about 6 other cases similar to the current case that had been reported as of December 2008 worldwide, but not published (Table 1). The Quality Assurance Department reported that the frequency of such incidents was 0.0015% (15 per million), with 6 incidents in 410,000 sales. It is unclear whether the manufacturer's safety guidelines were adhered to in these 6 previous cases.

It was ascertained that the multiple scan sequence of the MRI on Day 6 in the current case used a standard transmit/receive circular polarization head coil for the head scan, and a standard transmit body coil and receive neck array coil for the cervical spinal cord scan, with a 1.5-T unit (Magnetom Vision, Siemens AG). All the MR images were reviewed, and the examination protocols are summarized (with sequence parameters) in Table 2. A total of 430 images were obtained during this examination, with various pulse sequences used in both the axial and sagittal planes (Table 2). The actual whole-body-averaged SAR values were calculated based on the imaging parameters used and the weight of the patient by Siemens Japan K.K., and they ranged from 0.001 to 1.2938 W/kg. Only the highest value of 1.2938 W/kg, during cervical spinal cord imaging, exceeded the limit of 1.0 W/kg recom-

TABLE 1: Clinical summary of 6 cases of thermal injury related to the Codman MicroSensor after MRI*

Case No.	Country	Date of Event	MR Strength	MDR Description of Event or Problem	Device Evaluated	MDR Investigation Notes
1	Sweden	12/23/2002	1.5 T	Following placement, the patient was exposed to MRI and the magnetic field caused damage to the tip of the sensor. The tip of the sensor burned and broke. The heat around the tip of the sensor caused damage to the brain and further surgery was required to remove the broken sensor tip from the brain.	yes	The outer sheath of the sensor was burned and melted, apparently resulting from exposure to a high heat source. The heat source cannot be determined, although some form of electrical damage might be the root of the problem. The device could not be fully evaluated due to the extensive damage incurred.
2	Sweden	1/22/2003	1.5 T	The patient had a sensor implanted on 1/16/03. The sensor was not functioning on 1/22/03 when the patient was exposed to MRI. The sensor was burned and stuck in the patient's brain. The nylon catheter broke when the doctor tried to remove the sensor from the patient. A piece of the catheter remained in the patient's brain. The remaining piece had to be surgically removed on 1/23/03.	yes	The pressure sensor, case, and distal section of the catheter were returned for evaluation. The first 1.3 cm of the catheter appeared melted and the wires were broken. Several damaged areas of the catheter containing bends, kinks, and indentations were visible. Due to the damaged condition, no testing of the device was possible.
3	US	5/3/2004	unk	The sensor was placed following a craniotomy. The device functioned for 2 days & then the patient underwent MRI. Following MRI, the sensor did not work and examination found that the sensor wire had melted onto the patient's scalp. The sensor was discarded by the hospital following removal.	no	The sensor is not available for evaluation.
4	US	11/2003	unk	During MRI the patient became uncomfortable. When the MRI was completed, the patient's skin had blisters associated with burns where the ICP sensor had contacted the skin. It was observed that the sensor had melted and that this was the source of the burn on the patient's skin. Preliminary information indicated that the patient's neurological status appeared to be intact after the procedure.	no	The sensor is not available for evaluation.
5	US	3/2008	unk	The sensor stopped working after the patient underwent MRI. The sensor was removed and the portion of the catheter near the sensor was black and burned. The patient died due to a condition unrelated to the device.	yes	A portion of the sensor catheter was returned with the pressure sensor still attached to the end of the catheter. The portion of the catheter was covered with black matter, which was consistent in appearance with charred blood.
6	US	7/2008	unk	The sensor broke during MRI. A 1-cm burn was noted at the trocar exit site. The sensor was discarded by the hospital.	no	The sensor is not available for evaluation.

* These data were prepared by Johnson & Johnson K.K. Vigilance and Safety Group, Quality Assurance Department. Abbreviations: MDR = Medical Device Reporting; unk = unknown.

mended by the manufacturer. The total examination time was 48 minutes.

Although it became evident that the instruction manual that came with the ICP monitoring system used in the current case was the old version, which did not include any information about the correct configuration of the transducer or the recommended parameters for MRI, we concluded that the incident happened due to failure by medical doctors to follow the safety recommendations published by the manufacture. After the report from Johnson & Johnson, Codman Shurtleff, Inc., we devel-

oped a precautionary tag in cooperation with them, which clearly illustrates the correct configuration of the transducer and the important parameters for safe MR scanning. The manufacturer attached the tag to all display units in hospitals using this product in Japan immediately after it was produced.

Discussion

In the current case, an ICP transducer stopped functioning after MRI of the head and cervical spine on the

TABLE 2: Imaging parameters and calculated whole-body SAR of MRI in the current case*

Order	Area	Orientation	Sequence	TR	TE	FA	Matrix	No. of Images	Thickness (mm)	FOV (mm)	AT (sec)	SAR Limit (W/kg)	SAR (W/kg)†
1	head	axial 1, cor 1	scout	15	6	30	128×512	2	8	250	10	1.5	0.0039
2	head	sag 1	scout	150	14	70	128×512	1	8	250	22	1.5	0.0039
3	head	axial	T2	3800	99	180	176×512	19	6	220	64	1.5	0.0906
4	head	axial	T1	665	14	70	168×512	19	6	220	115	1.5	0.0906
5	head	axial	FLAIR	7000	105	180	168×512	19	5	220	175	1.5	0.0708
6	head	axial	T2FLASH	608	15	15	168×512	19	6	220	104	1.5	0.0010
7	head	axial	DWI slight		123	90	200×128	19	6	220	4	1.5	0.0134
8	head	axial	DWI strong		123	90	200×128	19	6	220	4	1.5	0.0167
9	head	sag	T1	570	14	70	192×512	19	6	220	113	1.5	0.0934
10	head	sag	T2	3700	99	180	198×512	19	6	220	70	1.5	0.0900
11	head	axial	MRA	35	7.2	20	235×1024	108	0.75	200	475	1.5	0.0996
12	neck	axial 1, cor 2, sag 1	scout	25	6	30	128×512	4	10	300	18	1.5	0.0039
13	neck	sag	T2	3900	112	150	210×1024	11	3	280	222	1.5	0.7985
14	neck	sag	T1	660	12	150	396×1024	11	3	280	159	1.5	1.2938
15	neck	axial	MRA	35	6	25	512×140	140	1.25	200	645	1.5	0.2185

* AT = acquisition time; cor = coronal; DWI = diffusion-weighted imaging; FA = flip angle; FLAIR = fluid-attenuated inversion recovery; FOV = field of view; MRA = MR angiography; sag = sagittal; TE = echo time; TR = repetition time.

† Data prepared by Siemens Japan K.K. The calculated actual whole-body-averaged SAR values ranged from 0.0010 to 1.2938 W/kg. Only the highest value of 1.2938 W/kg during cervical spinal cord scanning exceeded the 1.0 W/kg limit recommended by the manufacturer.

6th day of hospitalization (Day 6). The ICP transducer was melted and scorched when it was removed from the patient’s brain, and the wires had snapped. The patient developed a high fever and leukocytosis 3 days after the MRI study. Radiologists reported a low-density area in the left frontal lobe, at the previous location of the ICP transducer, on a head CT scan performed 4 days after the MRI study. No lesions had been seen at this location on either the head CT scan performed at the time of arrival or the MRI study performed on Day 6 (Fig. 1A–E). Contrast-enhanced CT performed on Day 27 and Gd-enhanced T1-weighted MR images obtained on Day 28 revealed a ring-enhancing lesion at the same location (Fig. 2B and D); T2-weighted MR images obtained on Day 28 revealed a central high-intensity tract inside a low-intensity center surrounded by a high-intensity small area, which corresponded to the shape and location of the tip of the ICP transducer. These findings were compatible with coagulative necrosis (Fig. 2E). We concluded that the ICP transducer had overheated and melted during the MRI procedure, causing thermal brain injury. Although definitive conclusions cannot be reached, it is distinctly possible that the meningitis was caused by exposure of the brain parenchyma to the nonsterile part of the transducer (titanium or copper inside the silicon- and nylon-coated tip). Alternatively, the meningitis may have been caused by insertion of a nonsterile transducer, or by contamination of the CSF during the right temporal lobectomy and decompressive craniectomy on Day 1. However, the timing of the onset of meningitis seems slightly too late for it to be related to the transducer insertion or surgery.

There have been many reports of thermal injuries associated with MRI.^{3,8–11,20,22,25–27} Electrocardiography

leads, electrodes, pulse oximeters, thermodilution Swan-Ganz catheters, intravascular guidewires, DBS electrodes, and other devices that use conductive leads, wires, and cables have been reported to be associated with thermal injuries. Unfortunately, inappropriate use of monitoring devices during MRI is often the cause of thermal injuries. However, to our knowledge, no serious thermal brain injuries associated with ICP transducers have previously been reported after MRI.

According to Maxwell’s theory of electromagnetism, heating can be caused by the RF radiation used in MRI by 3 mechanisms. The first mechanism is electromagnetic induction heating, whereby a change in the flux of the magnetic induction through a conducting medium gives rise to an electromotive force that lasts as long as the flux is changing.^{4,5,12,23} Radiofrequency radiation produces eddy currents in each volume of the conducting specimen. These circulating currents cause power loss by ohmic heating. Formation of a loop in the monitoring cable increases the circuit’s inductance, which induces larger currents with greater heating of the cable. The second mechanism is electromagnetic induction heating of a circuit in resonance.^{4,5,12,23} Maximum electromagnetic induction heating occurs when the circuit is in the resonant condition, resulting in induction of the maximum current. The third mechanism is heating of conductors by resonant RF waves, known as the “antenna effect.”^{24,5,18,31} The monitoring cable can be considered as an RF wire antenna that is sensitive to the electrical component, rather than the magnetic component, of the RF radiation used for MRI. The incident RF wave enters the antenna and is bounced back at the open ends of the wire, causing reflected RF waves to travel back and forth along the longi-

tudinal axis of the structure and form standing RF waves. Thus, in contrast to the first and second mechanisms, in this mechanism storage of electrical energy occurs in the wire. The additional electrical field induced by the current in this antenna has a maximum field line density at the antenna tip.

After insertion of the Codman MicroSensor transducer into the patient's brain parenchyma, we configured the transducer in a straight line (without any coiling of the nylon-coated sensor lead wires) and taped it to his neck (Fig. 4 left). We speculate that the major mechanism of the incident in the current case was the antenna effect, because there were no burns where the transducer was attached to the patient's skin, and only the tip of the transducer in his brain parenchyma was melted and scorched. Furthermore, resonance occurs most effectively when the length of one rotation of a receive coil is a multiple of λ , $\lambda/2$, or $\lambda/4$, where λ is the RF wavelength of the scanner. The total length of the Codman MicroSensor ICP transducer is 1105 mm, which is close to $\lambda/4$ (1180 mm) for a 1.5-T, 63.5-MHz MRI scanner.

Surgically implanted neurostimulators and electrodes may be used to provide functional electrical stimulation, and have been tested for safety in patients undergoing MRI scanning.^{6,20,24} Spiegel et al. reported transient dystonia and Henderson et al. reported permanent neurological deficit after MRI scanning in patients with implanted DBS electrodes for the treatment of Parkinson disease.^{9,20,22,27} Spiegel et al.²⁷ speculated that the antenna effect had been the cause of the incident in their case. Achenbach et al.¹ reported a temperature increase at the tip of a pacing electrode, unattached to a cardiac pacing pulse generator, of up to 63.1°C within 90 seconds of starting MRI scanning. This phenomenon was also thought to be caused by the antenna effect. More recently, Luechinger et al.¹³ thoroughly analyzed the heating of myocardium-pacemaker lead tips in in vivo experiments during MRI, and concluded that none of the leads were safe with respect to heating. Nakamura et al.¹⁵ measured the induced current in 7 types of loops in conductive leads in in vitro experiments, and reported that a carbon film resistor inserted into the circuit in the bore of a 0.5-T whole-body MR scanner sparked and burned out. The results implied that simple loops of conductive material with another inserted conductive material may result in the induction of a large and hazardous voltage in the scanner. The Codman MicroSensor ICP transducer is similar to the implanted DBS electrodes used in the treatment of Parkinson disease in that it is placed in the brain parenchyma, and it is similar to metallic guidewires or pacing electrodes in form and materials. In our case, a rapid temperature increase at the tip of the transducer may have exceeded the melting point of the nylon-11 (187°C) and copper (1084.62°C) that the transducer was composed of, because the transducer had melted and snapped.

The alarming reports mentioned above, in which patients with DBS implants experienced adverse effects after MRI, demonstrate the crucial importance of strictly following the manufacturers' guidelines.^{9,20,22,27} In the case reported by Spiegel et al.,²⁷ a transmit/receive head coil was used, and the scan was performed at 1.0 T (not

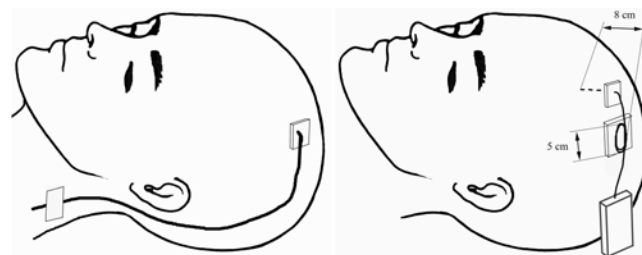


Fig. 4. **Left:** The configuration of the transducer in the current case. After insertion of the Codman MicroSensor into the patient's brain parenchyma, we configured the transducer in a straight line, without coils, and taped it to his neck. **Right:** Drawing of the configuration for MRI based on the manufacturer's recommendations and guidelines. (See *Appendix* for specific details.)

the recommended 1.5 T). In the case reported by Henderson et al.,⁹ the patient had one pulse generator implanted in the abdomen and another implanted infraclavicularly and underwent MRI of the spine at 1.0 T with a transmit/receive body coil (not the recommended transmit/receive RF head coil). In the present case, 3 aspects of the MRI procedure did not follow the manufacturer's guidelines (see *Appendix* for the most recent English-language version of the addendum to the instructions for use, as of September 24, 2012). First, we configured the transducer in a straight line without coiling a part of it and taped it to the patient's neck, because we thought that loop formation should always be avoided in the MRI suite (Fig. 4 left). Looping a wire increases its inductance, and it is commonly thought that the pulsed magnetic gradient fields and pulsed RF fields used by MRI units may induce sufficient current in an electrically conductive loop to result in thermal or electrical burn injuries. However, a straight-line configuration is contraindicated for this device (*Appendix*). We should have left a straight segment approximately 8 cm in length from the tip of the implanted transducer and coiled the remaining Codman MicroSensor near the base of the connector into 5 or 6 loops approximately 5 cm in diameter (Fig. 4 right; *Appendix*). Although the recommended geometry may induce a current in the loops, this current would flow in the opposite direction to the current that might be induced by the static and gradient magnetic fields. Second, cervical spine MRI was performed with a standard transmit body coil and a receive neck array coil (surface coil). These conditions also deviated substantially from the manufacturer's MRI safety guidelines (*Appendix*) and may be the cause of the high SAR (Table 2). Third, the whole-body SAR limit in our 1.5-T unit (Magnetom Vision, Siemens AG) was 1.5 W/kg at that time. Although this value was in accord with the MRI safety guidelines determined by the International Electrotechnical Commission, the FDA,²⁹ and the Ministry of Health, Labor, and Welfare in Japan, it was higher than the maximum of 1.0 W/kg recommended in the manufacturer's safety guidelines (*Appendix*). Evidence has accumulated that the whole-body SAR limit is an unreliable indicator of implant safety and that using this limit alone as a safety recommendation is potentially dangerous.^{2,17} However, the highest SAR value of 1.2938 W/kg in one series of spinal cord scans, which was more than the recommended 1.0 W/kg, may have

been one of the causes of overheating of the transducer tip in the current case. The SAR limit recommended by the FDA and the International Electrotechnical Commission has recently been deregulated. Therefore, the whole-body-averaged SAR limit of 1.0 W/kg in the manufacturer's guidelines for the Codman MicroSensor seems to be slightly too strict. If this SAR limit is adhered to, it will be necessary to consider alternative scan sequences, which decrease the whole-body-averaged SAR, to maintain the quality of MR images.

Conclusions

Many factors should be taken into consideration when performing MRI in a patient with an implanted device. Moreover, we should not be influenced by preconceptions that loop formation must be avoided at all times during MRI. Any deviations from the manufacturer's safety guidelines may result in serious injury to the patient. We emphasize the crucial importance of strictly and carefully adhering to safety guidelines when performing MRI on a patient with an implanted ICP monitoring device, to prevent catastrophic incidents, including the possibility of meningitis, transient dystonia, paralysis, coma, or even death following thermal brain injury.

Appendix

The *Appendix* follows the last page of this article.

Acknowledgments

The authors thank Mr. Seiichiro Ohno of Central Division of Radiology, Okayama University Hospital, for his technical support; Mr. Ryuji Sakai of Siemens Japan K.K., for his helpful comments; and Ms. Maiko Toyama of Johnson & Johnson, Inc., for her assistance.

Disclosure

The authors report no conflict of interest concerning the materials or methods used in this study or the findings specified in this paper.

Author contributions to the study and manuscript preparation include the following. Conception and design: Tanaka, Yumoto, Shiba, Okawa, Ichikawa, Tokunaga. Acquisition of data: Tanaka, Yumoto, Shiba. Analysis and interpretation of data: Tanaka, Okawa, Yasuhara, Tokunaga, Ujike. Drafting the article: Tanaka. Critically revising the article: all authors. Reviewed submitted version of manuscript: all authors. Approved the final version of the manuscript on behalf of all authors: Tanaka. Study supervision: Date, Ujike.

References

1. Achenbach S, Moshage W, Diem B, Bieberle T, Schibgilla V, Bachmann K: Effects of magnetic resonance imaging on cardiac pacemakers and electrodes. *Am Heart J* **134**:467–473, 1997
2. Baker KB, Tkach JA, Nyenhuis JA, Phillips M, Shellock FG, Gonzalez-Martinez J, et al: Evaluation of specific absorption rate as a dosimeter of MRI-related implant heating. *J Magn Reson Imaging* **20**:315–320, 2004
3. Bashein G, Syrory G: Burns associated with pulse oximetry during magnetic resonance imaging. *Anesthesiology* **75**:382–383, 1991 (Letter)

4. Dempsey MF, Condon B: Thermal injuries associated with MRI. *Clin Radiol* **56**:457–465, 2001
5. Dempsey MF, Condon B, Hadley DM: Investigation of the factors responsible for burns during MRI. *J Magn Reson Imaging* **13**:627–631, 2001
6. Finelli DA, Rezai AR, Ruggieri PM, Tkach JA, Nyenhuis JA, Hrdlicka G, et al: MR imaging-related heating of deep brain stimulation electrodes: in vitro study. *AJNR Am J Neuroradiol* **23**:1795–1802, 2002
7. Gelabert-González M, Ginesta-Galan V, Sernamito-García R, Allut AG, Bandin-Diéguez J, Rumbo RM: The Camino intracranial pressure device in clinical practice. Assessment in a 1000 cases. *Acta Neurochir (Wien)* **148**:435–441, 2006
8. Hall SC, Stevenson GW, Suresh S: Burn associated with temperature monitoring during magnetic resonance imaging. *Anesthesiology* **76**:152, 1992 (Letter)
9. Henderson JM, Tkach J, Phillips M, Baker K, Shellock FG, Rezai AR: Permanent neurological deficit related to magnetic resonance imaging in a patient with implanted deep brain stimulation electrodes for Parkinson's disease: case report. *Neurosurgery* **57**:E1063, 2005
10. Kanal E, Shellock FG: Burns associated with clinical MR examinations. *Radiology* **175**:585, 1990 (Letter)
11. Knopp MV, Essig M, Debus J, Zabel HJ, van Kaick G: Unusual burns of the lower extremities caused by a closed conducting loop in a patient at MR imaging. *Radiology* **200**:572–575, 1996
12. Konings MK, Bartels LW, Smits HFM, Bakker CJG: Heating around intravascular guidewires by resonating RF waves. *J Magn Reson Imaging* **12**:79–85, 2000
13. Luechinger R, Zeijlemaker VA, Pedersen EM, Mortensen P, Falk E, Duru F, et al: In vivo heating of pacemaker leads during magnetic resonance imaging. *Eur Heart J* **26**:376–383, 2005
14. Macmillan CSA, Wild JM, Andrews PJD, Marshall I, Armitage PA, Wardlaw JM, et al: Accuracy of a miniature intracranial pressure monitor, its function during magnetic resonance scanning, and assessment of image artifact generation. *Neurosurgery* **45**:188–193, 1999
15. Nakamura T, Fukuda K, Hayakawa K, Aoki I, Matsumoto K, Sekine T, et al: Mechanism of burn injury during magnetic resonance imaging (MRI)—simple loops can induce heat injury. *Front Med Biol Eng* **11**:117–129, 2001
16. Newcombe VFJ, Hawkes RC, Harding SG, Willcox R, Brock S, Hutchinson PJ, et al: Potential heating caused by intraparenchymal intracranial pressure transducers in a 3-tesla magnetic resonance imaging system using a body radiofrequency resonator: assessment of the Codman MicroSensor Transducer. Technical note. *J Neurosurg* **109**:159–164, 2008
17. Nitz WR, Brinker G, Diehl D, Frese G: Specific absorption rate as a poor indicator of magnetic resonance-related implant heating. *Invest Radiol* **40**:773–776, 2005
18. Nitz WR, Oppelt A, Renz W, Manke C, Lenhart M, Link J: On the heating of linear conductive structures as guide wires and catheters in interventional MRI. *J Magn Reson Imaging* **13**:105–114, 2001
19. Piper I, Barnes A, Smith D, Dunn L: The Camino intracranial pressure sensor: is it optimal technology? An internal audit with a review of current intracranial pressure monitoring technologies. *Neurosurgery* **49**:1158–1165, 2001
20. Rezai AR, Baker KB, Tkach JA, Phillips M, Hrdlicka G, Sharan AD, et al: Is magnetic resonance imaging safe for patients with neurostimulation systems used for deep brain stimulation? *Neurosurgery* **57**:1056–1062, 2005
21. Rezai AR, Finelli D, Nyenhuis JA, Hrdlicka G, Tkach J, Sharan A, et al: Neurostimulation systems for deep brain stimulation: in vitro evaluation of magnetic resonance imaging-related heating at 1.5 tesla. *J Magn Reson Imaging* **15**:241–250, 2002

22. Rezai AR, Phillips M, Baker KB, Sharan AD, Nyenhuis J, Tkach J, et al: Neurostimulation system used for deep brain stimulation (DBS): MR safety issues and implications of failing to follow safety recommendations. **Invest Radiol** **39**:300–303, 2004
23. Shellock FG: Radiofrequency energy-induced heating during MR procedures: a review. **J Magn Reson Imaging** **12**:30–36, 2000
24. Shellock FG, Cosendai G, Park S-M, Nyenhuis JA: Implantable microstimulator: magnetic resonance safety at 1.5 Tesla. **Invest Radiol** **39**:591–599, 2004
25. Shellock FG, Kanal E: Burns associated with the use of monitoring equipment during MR procedures. **J Magn Reson Imaging** **6**:271–272, 1996
26. Shellock FG, Slimp GL: Severe burn of the finger caused by using a pulse oximeter during MR imaging. **AJR Am J Roentgenol** **153**:1105, 1989 (Letter)
27. Spiegel J, Fuss G, Backens M, Reith W, Magnus T, Becker G, et al: Transient dystonia following magnetic resonance imaging in a patient with deep brain stimulation electrodes for the treatment of Parkinson disease. Case report. **J Neurosurg** **99**:772–774, 2003
28. Stendel R, Heidenreich J, Schilling A, Akhavan-Sigari R, Kurth R, Picht T, et al: Clinical evaluation of a new intracranial pressure monitoring device. **Acta Neurochir (Wien)** **145**:185–193, 2003
29. US Department of Health and Human Services, Food and Drug Administration, Center for Devices and Radiological Health: **Guidance for Industry and FDA Staff. Criteria for Significant Risk Investigations of Magnetic Resonance Diagnostic Devices.** (<http://www.fda.gov/downloads/MedicalDevices/DeviceRegulationandGuidance/GuidanceDocuments/ucm072688.pdf>) [Accessed September 5, 2012]
30. Williams EJ, Bunch CS, Carpenter TA, Downey SP, Kendall IV, Czosnyka M, et al: Magnetic resonance imaging compatibility testing of intracranial pressure probes. Technical note. **J Neurosurg** **91**:706–709, 1999
31. Yeung CJ, Atalar E: RF transmit power limit for the barewire loopless catheter antenna. **J Magn Reson Imaging** **12**:86–91, 2000

Manuscript submitted April 11, 2012.

Accepted September 4, 2012.

Portions of this work were presented orally at the 37th Annual Meeting of the Japanese Association of Acute Medicine, Iwate, Japan, October 30, 2009.

Please include this information when citing this paper: published online October 12, 2012; DOI: 10.3171/2012.9.JNS12738.

Address correspondence to: Reiichiro Tanaka, M.D., Department of Critical Care and Emergency Medicine, Okayama University Hospital, 2-5-1 Shikata-Cho, Kita-ku, Okayama 700-8558, Japan. email: Rtanaka17@aol.com.

Appendix

ENGLISH

ADDENDUM SHEET

CODMAN® MicroSensor Products

Catalog no. 82-6631, 82-6632, 82-6633, 82-6638, 82-6639 and 82-6653

The following information pertains to Instructions for Use #171976-001, 171977-001, 171978-001, 197138-001 and 197605-001.

Addition to WARNINGS section:

Before conducting an MRI procedure on a patient with an implanted CODMAN MicroSensor, read the *MRI Safety* section. Failure to read and strictly adhere to these guidelines can result in serious injury to the patient.

Remove the following CONTRAINDICATION:

Compatibility of implantable catheter-tipped pressure transducers with magnetic resonance imaging (MRI) has not been determined.

Add the following section:

MRI Safety

CAUTION: These guidelines apply to MRI (magnetic resonance imaging) procedures conducted in a 1.5 tesla MR system, **ONLY**. Higher magnetic field systems have not been tested and may cause burn or serious injury.

IMPORTANT: The CODMAN MicroSensor connector will cause substantial image artifact and distortion on the MR image. As such, position the connector away from the anatomy of interest during the MRI procedure. The CODMAN MicroSensor Skull Bolt is a steel bolt included with catalog no. 82-6638 and 82-6639. It will cause substantial image artifact and distortion on the MR image in the proximity of the bolt. Optimize MR imaging parameters for the presence of the metallic device.

The ability to safely perform an MRI procedure on a patient with an implanted CODMAN MicroSensor has been demonstrated when the following guidelines are followed:

1. Immediately prior to entering the MR environment, verify that the CODMAN MicroSensor is functioning properly. **DO NOT perform an MRI procedure if the CODMAN MicroSensor is damaged or otherwise not functioning properly.**
2. Disconnect all cables and patient monitoring devices attached to the CODMAN MicroSensor before transporting the patient into the MR environment.
3. The CODMAN MicroSensor must be placed in a specific geometry to minimize the potential for excessive heating of the sensor tip. Leave a straight segment approximately 8 cm in length, as measured from the tip of the implanted sensor. Coil the remaining CODMAN MicroSensor near the base of the connector into 5 or 6 loops approximately 5 cm in diameter. Center the coil on the top of the patient's head. See Figure 1. Do not perform MRI with the CODMAN MicroSensor in a "straight line" configuration. **Failure to follow this guideline can result in serious injury to the patient.**
4. Use a dry gauze pad at least 1 cm thick to insulate the patient's tissue from the coiled CODMAN MicroSensor and connector. If using tape to secure the sensor to the insulating pad, use care when removing the tape to prevent damage to the CODMAN MicroSensor.
5. Use only the following types of radio frequency coils for the MRI procedure:
 - a. Transmit / receive RF body coil
 - b. Transmit body coil / receive-only head coil
 - c. Transmit / receive head coil
6. Set MRI parameters to the lowest usable whole body averaged SAR level. **CAUTION: Do not exceed an RF (radio frequency) WHOLE BODY AVERAGED SAR (specific absorption rate) or RF HEAD AVERAGED SAR of 1.0 W/kg.**

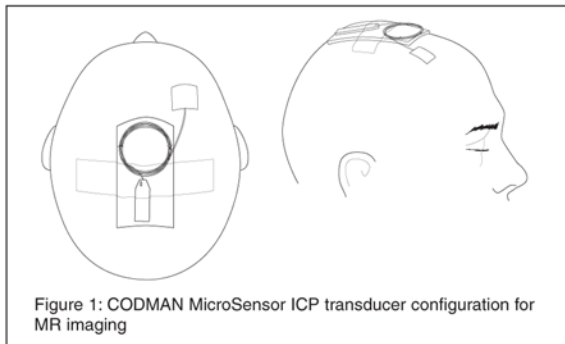


Figure 1: CODMAN MicroSensor ICP transducer configuration for MR imaging

Disclaimer

Codman distributes this addendum to the Instructions for Use only outside of the United States. This addendum has not been cleared by the US Food and Drug Administration for use in the US. This addendum to the Instructions for Use is current as of the date that permission was granted to use this material in this publication [September 24, 2012].

LCN 204704-001/D
 © 2005–2011 Codman & Shurtleff, Inc.
 Revised 04/11